



**PATIENT PRESENTING CLINICAL SIGNS**

Lucky Seppi History: Few episodes of vomiting, lethargy, dark brown urine.

**SPECIES** Physical Examination: N/A.

Canine Urinalysis: N/A.

CBC: Hematocrit 31%, neutrophilia, eosinopenia, basophilia.

**BREED** Serum Biochemistry: Elevated albumin and bilirubin.

Golden Retriever Radiographic Findings: Normal thorax, mass mid right abdomen.

**SEX**

MN

**AGE**

9 years

**WEIGHT**

70 #

**INTERPRETED BY**

Remo Lobetti, BVSc,  
MMedVet (Med), PhD, Dipl.  
ECVIM

**ULTRASONOGRAPHIC EXAMINATION OF THE ABDOMEN**

**Urinary System**

Full urinary bladder with a normal thickness and appearance of the wall. Normal anechoic urine with no sediment or uroliths evident.

Normal trigone area, proximal urethra, and iliac blood vessels.

Normal iliac lymph nodes. Ureters not visualized.

Normal renal size (left 7 cm, right 7.9 cm), echogenic appearance, cortico-medullary differentiation, pelvis, and capsule.

**Reproductive System**

Small hypoechogenic prostate.

**IMAGING PERFORMED BY**

Dr Megan Cassels-Conway,  
DVM

**Adrenal Glands**

Left – normal shape, echogenic appearance, position, and size (2.11 x 0.64 cm).

Right – large irregular mottled echogenic mass (7.3 x 9 cm).

**HOSPITAL NAME**

Central Broward Animal  
Hospital

**Spleen**

Normal size and echogenic appearance. Smooth homogenous parenchyma, regular curvilinear capsule, and normal vasculature. No evidence of inflammatory, neoplastic, infarction, or infiltrative changes noted.

**REFERRING VET**

Dr Megan Cassels-Conway,  
DVM

**Liver**

Normal size, echogenic appearance, portal markings, and curvilinear capsule. No nodules or masses evident. Full gall bladder containing normal anechoic bile. Normal appearance and thickness of the gall bladder wall. Normal bile duct.

**INVOICE**

303177

**Gastrointestinal**

**DATE**

8/9/22

Normal appearance of the stomach, duodenum, small intestine, ileo-cecal junction, and colon with no loss of layering, normal wall thickness and peristaltic activity, and no distension of the lumen.



**PATIENT** *Pancreas*

Lucky Seppi Normal size and echogenic appearance. Normal echogenic appearance of the mesentery and fat surrounding the pancreas.

**SPECIES** *Free Abdomen*

Canine No mesenteric lymphadenomegaly.  
Small amount of acellular ascites around the right kidney.

**BREED**

Golden Retriever

**ULTRASONOGRAPHIC FINDINGS**

Primary Findings:

**SEX**

- Adrenal mass.
- Ascites.

MN

**AGE**

Secondary Findings:

9 years

- None.

**WEIGHT**

70 #

**INTERPRETATION OF THE FINDINGS & FURTHER RECOMMENDATIONS**

Etiologies for the right adrenal mass would be non-functional carcinoma and pheochromocytoma.

The ascites can be ascribed to the adrenal mass.

Further assessment would be blood pressure, blood and urine catecholamine assay, and if surgery is being considered, then possibly a CT scan.

Specific therapy would be dependent on an etiological diagnosis.

**INTERPRETED BY**

Remo Lobetti, BVSc,  
MMedVet (Med), PhD, Dipl.  
ECVIM

**IMAGING PERFORMED BY**

Dr Megan Cassels-Conway,  
DVM

**HOSPITAL NAME**

Central Broward Animal  
Hospital

**REFERRING VET**

Dr Megan Cassels-Conway,  
DVM

**INVOICE**

303177

**DATE**

8/9/22



**PATIENT**

Lucky Seppi

**SPECIES**

Canine

**BREED**

Golden Retriever

**SEX**

MN

**AGE**

9 years

**WEIGHT**

70 #

**INTERPRETED BY**

Remo Lobetti, BVSc,  
MMedVet (Med), PhD, Dipl.  
ECVIM

**IMAGING PERFORMED BY**

Dr Megan Cassels-Conway,  
DVM

**HOSPITAL NAME**

Central Broward Animal  
Hospital

**REFERRING VET**

Dr Megan Cassels-Conway,  
DVM

**INVOICE**

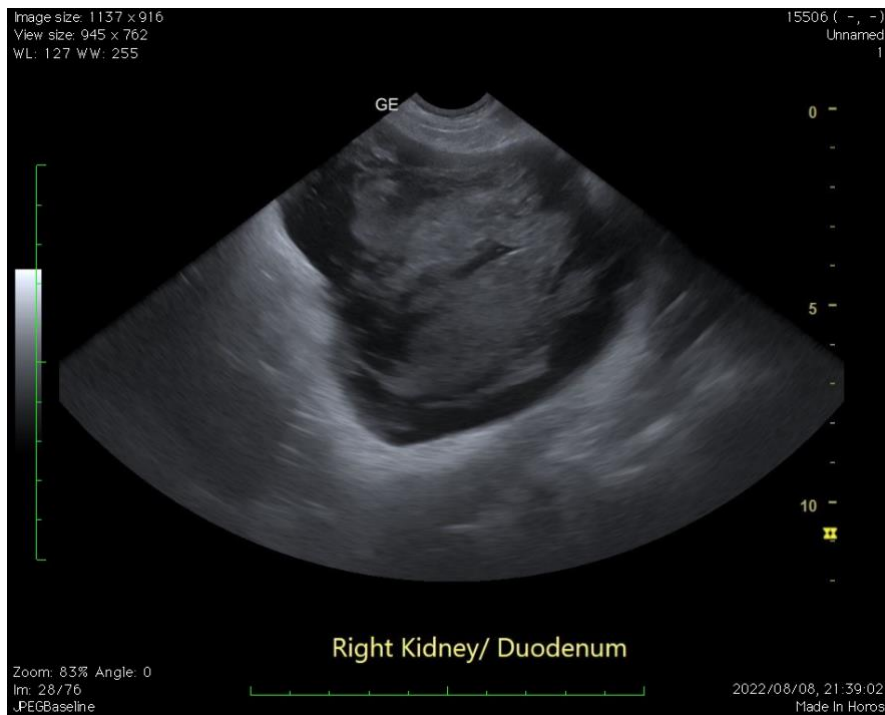
303177

**DATE**

8/9/22

**IMAGES**

**Right adrenal**



The information and recommendations provided are based on the images presented by the referring veterinarian. No evaluation can be communicated regarding pathology that was not visible in the image/video clips provided.

Thank you for this referral. If the clinical or image interpretation does not parallel your findings or if I can be of any further assistance, please contact me.

**Remo Lobetti, BVSc, MMedVet (Med), PhD, Dipl. ECVIM (Internal Medicine)**  
[rlobetti@mweb.co.za](mailto:rlobetti@mweb.co.za)